



## Studies on hepatoprotective effect of *Flaveria trinervia*

S. Umadevi<sup>1</sup>, G. P. Mohanta<sup>\*1</sup>, R. Kalaiselvan<sup>1</sup>, P. K. Manna<sup>1</sup>, R. Manavalan<sup>1</sup>, S. Sethupathi<sup>2</sup>,  
K. Shantha<sup>2</sup>

<sup>1</sup> Department of Pharmacy, Annamalai University, Annamalai Nagar, Tamil Nadu.

<sup>2</sup> Department of Medical Biochemistry, Annamalai University, Annamalai Nagar, Tamil Nadu - 608 002.

### Abstract

**Objective:** To evaluate the hepatoprotective effect of leaf extract of *Flaveria trinervia* in rat. **Materials and methods:** The methanolic extract of the plant was evaluated for the hepatoprotective activity against carbon tetrachloride (CCl<sub>4</sub>)-induced liver damage in rats by administering orally at 400 mg/kg dose for 10 days. Such effect was compared with silymarin as a standard hepatoprotective drug. In the serum, glutamate oxaloacetate transaminase, glutamate pyruvate transaminase, alkaline phosphatase, total protein, albumin, triglyceride and cholesterol contents were determined. In the liver, total protein, peroxide, phospholipid and glutathione levels were estimated. **Results:** The extract significantly reversed the elevated enzyme levels and altered biochemical parameters compared to control and silymarin. Besides, a significant reduction of the CCl<sub>4</sub>-induced changes in the liver histopathology was also observed. **Conclusion:** The extract showed a considerable potential for hepatoprotective activity possibly by the antioxidant property.

**Keywords:** *Flaveria trinervia*, hepatoprotective, silymarin, carbon tetrachloride.

### 1. Introduction

*Flaveria trinervia* (Asteraceae) is an dichotomously branched herb. Leaves are opposite, oblong, auricled at base, dentate. The plant is native to Australia, and is widely distributed in Chengalpattu, Coimbatore, Dharmapuri, Salem, Tiruchirappalli and Tirunelveli (Tamil Nadu). It is reported that the leaf juice of the plant is used to overcome jaundice [1]. It is also claimed to be useful in skin diseases [1]. No systematic studies on the

liver protective activity of *Flaveria trinervia* leaf [2] and hence, this formed the basis to take up the study.

CCl<sub>4</sub> has been one of the most commonly used toxins in the experimental study of liver disease. The hepatotoxicity of CCl<sub>4</sub> is mediated through its initial reduction by cytochrome-p450 to toxic trichloromethyl radicals. These radicals can react directly with polyunsaturated fatty acids or other

\*Corresponding author

E-mail: gpmohanta@yahoo.com

cellular components, thus damaging the liver [3]. In the present study  $\text{CCl}_4$  was employed to produce liver toxicity.

## 2. Materials and methods

### 2.1 Plant material

The plant material of *F. trinervia* was collected from Tirunelveli, Tamil Nadu, in January 2003 and authenticated by Dr. C. Chelladurai, survey of medicinal plants unit (CCRAS), palayamkottai, Tamil Nadu. A voucher specimen of the plant has been deposited in the department of pharmacy, Annamalai University, Tamil Nadu.

### 2.2 Preparation of extract

Dried and coarsely powdered plant leaves of *F. trinervia* were extracted with methanol. The methanolic extract was concentrated under reduced pressure and dried. The percentage yield of extract was 13.5% w/w. The extract was made in to suspension with 1% carboxy methyl cellulose (CMC) in distilled water and used for the experiment.

### 2.3 Preliminary phytochemical test

The preliminary investigation of extract found to contain flavonoids, tannin, phenol and carbohydrate.

### 2.4 Animals

Wistar strain of male rats 130-180 g, maintained under uniform conditions of light and temperature were used during this study. They were allowed to feed on standard diet and water *ad libitum*. Experimental protocols were approved by the Institutional Animal Ethical Committee.

### 2.5 Hepatoprotective activity

The experiment was performed following the modified method of Subrata De. *et al* [4]. Animals were divided in to five groups of six rats each. Group I was kept as control and distilled water was administered orally for 10

days. To the II group 1% CMC was administered per oral (p.o.) for ten days. Group III, IV and V received 0.7 ml/kg of  $\text{CCl}_4$  intraperitoneally (i.p.) from third day to tenth day. Group IV was treated with the extract (400 mg/kg p.o.) and group V received silymarin (200 mg/kg p.o., suspended in 1% CMC) for ten days.

Silymarin or extract treatment was started two days prior to  $\text{CCl}_4$  administration and continued till the end of the experiment. The rats were sacrificed one hour after the last  $\text{CCl}_4$  injection, by cervical dislocation and the blood was collected by the ocular puncture followed by separation of serum and plasma. Half of the liver tissue was transferred into 10% formalin solution and the remaining in saline solution, for histopathological study and evaluation of biochemical parameters respectively.

The activities of serum marker enzymes namely GOT, GPT and ALP were assayed in serum using standard kits from Lupin Laboratories and Pointe Scientific respectively. The levels of protein and albumin were estimated in serum using standard kits from Ranboxy Laboratories [5]. Other biochemical parameters such as, triglyceride [6], cholesterol [7], protein [8], peroxide [9], glutathione [10] and phospholipid [11] were determined. The liver tissues were processed following standard procedures [6] for histopathological examination.

### 2.6 Statistical analysis

Results were expressed as mean  $\pm$  SEM. An one way analysis of variance (ANOVA) was performed to find out the difference between the means and the level of significance was set at  $p < 0.05$ .

## 3. Results

The levels of GPT, GOT on  $\text{CCl}_4$  administration were elevated compared to the corresponding normal value, but there was no such significant

Table 1.

Hepatoprotective effect of *Flaveria trinervia* on serum parameters in CCl<sub>4</sub> treated rats.

Parameter	Control	1% CMC	CCl <sub>4</sub>	Methanolic extract	Silymarin
GPT U/L	52 ± 1.23	54.4 ± 2.73	96.3 ± 1.45*	61.2 ± 1.33 <sup>a</sup>	52.5 ± 4.16 <sup>a</sup>
GOT U/L	134.5 ± 2.04	124.3 ± 1.17	286 ± 2.41*	154 ± 1.49 <sup>a</sup>	139.3 ± 0.77 <sup>a</sup>
ALP U/L	264.6 ± 1.45	284 ± 0.67	259.6 ± 1.24*	295.6 ± 0.49 <sup>a</sup>	364 ± 1.23 <sup>a</sup>
Cholesterol mg/dl	84.2 ± 2.73	84.6 ± 1.86	35.23 ± 0.56*	69.73 ± 3.05 <sup>a</sup>	73.3 ± 0.13 <sup>a</sup>
Triglyceride mg/dl	20.63 ± 3.06	22.5 ± 0.06	15.6 ± 2.73*	19.5 ± 1.48 <sup>a</sup>	21.73 ± 2.62 <sup>a</sup>
Protein g/dl	7.77 ± 0.28	7.47 ± 2.16	5.73 ± 0.34*	6.9 ± 0.02 <sup>a</sup>	7.5 ± 1.03 <sup>a</sup>
Albumin g/dl	4.43 ± 0.13	4.4 ± 1.17	3.23 ± 0.24*	3.83 ± 0.08 <sup>a</sup>	4.17 ± 0.20 <sup>a</sup>

Values are expressed as mean ± SEM: (n=6);

\*P<0.05 compared to control group; <sup>a</sup>P< 0.05 compared to CCl<sub>4</sub> group.

Table 2.

Hepatoprotective effect of *Flaveria trinervia* on certain liver parameters in CCl<sub>4</sub> treated rats.

Parameter	Control	1% CMC	CCl <sub>4</sub>	Methanolic extract	Silymarin
Protein mg/g tissue	6.24 ± 0.05	6.3 ± 2.001	5.89 ± 2.01*	7.78 ± 1.01 <sup>a</sup>	6.82 ± 0.02 <sup>a</sup>
Peroxide nmol/g of protein	30.15 ± 2.8	29.65 ± 3.56	116.67 ± 2.5*	76.51 ± 2.79 <sup>a</sup>	52.27 ± 0.51 <sup>a</sup>
Glutathione μ mol/mg of protein	0.045 ± 0.01	0.03 ± 1.04	0.05 ± 0.02	0.04 ± 0.05	0.037 ± 2.01
Phospholipid μ mol/mg of protein	1.09 ± 0.39	0.98 ± 1.06	0.34 ± 0.12*	0.83 ± 0.04 <sup>a</sup>	0.91 ± 0.05 <sup>a</sup>

Values are expressed as mean ± SEM: (n=6);

\*P<0.05 compared to control group; <sup>a</sup>P< 0.05 compared to CCl<sub>4</sub> group;

rise in ALP level. The extract and silymarin treated group significantly reduced the elevated levels of GPT and GOT. The values are presented in table 1.

Observations on CMC treated group were almost similar to that of control group. Phospholipid, serum protein, albumin, triglyceride and cholesterol contents decreased on CCl<sub>4</sub> treated group compared to the normal, however significant increase in the level of phospholipid, protein, albumin, triglyceride and cholesterol levels after treatment with plant extract was observed.

Peroxide levels were higher than the normal value on CCl<sub>4</sub> treatment but the levels were decreased after administration of plant extract or silymarin. Glutathione levels were not affected in CCl<sub>4</sub> treated groups (Table 2).

In the morphological study, the liver was appeared to be pale in color in the CCl<sub>4</sub> treated group. However no such remarkable difference in morphology was observed in drug treated group compared to control.

The control group showed normal liver histology (Fig 1). Radiating arrangements of hepatocytes in CCl<sub>4</sub> group got disrupted. Macro vesicular

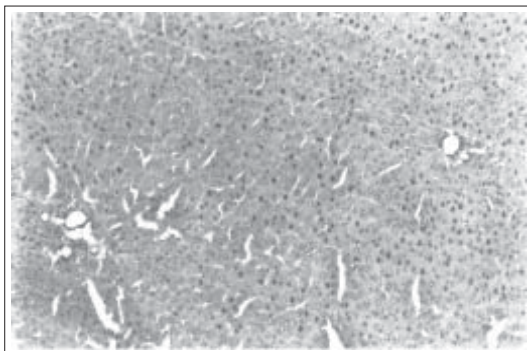
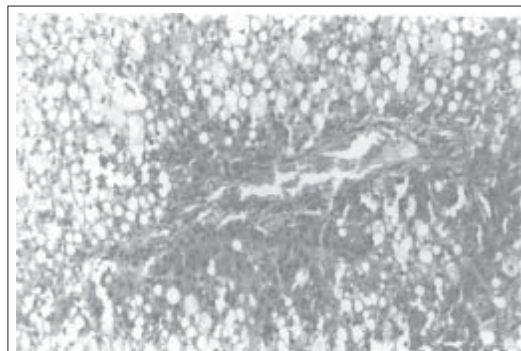
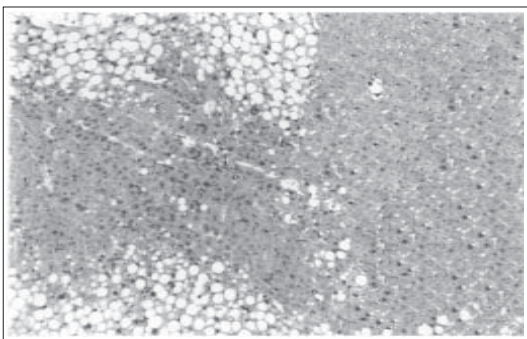
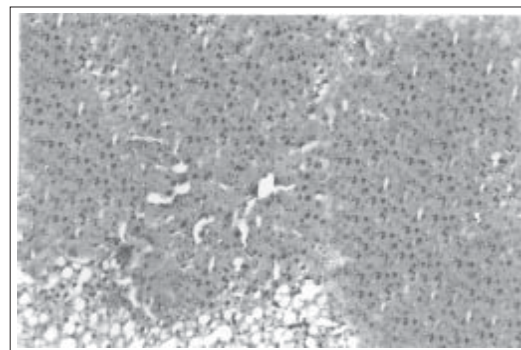


Fig. 1. Liver tissue of control rats 10X10x=100x

Fig. 2. Liver tissue of CCl<sub>4</sub> treated animals 10X10x=100xFig. 3. Liver tissue of rats treated with CCl<sub>4</sub> and *Flaveria trinervia* 10X10x=100xFig. 4. Liver tissue of rats treated with CCl<sub>4</sub> and silymarin 10X10x=100x

fatty changes were seen essentially (Fig 2). In extract treated group degeneration areas are lesser and fatty changes are also lesser when compared to CCl<sub>4</sub> group (Fig 3). The histopathological response to the methanolic extract of leaves of *F.trinervia* was comparable to that observed with the silymarin (Fig 4). It shows moderate protection in CCl<sub>4</sub>-induced liver damage.

#### 4. Discussion

The effect of *F. trinervia* on CCl<sub>4</sub>-induced toxic system was examined and compared with that of silymarin which is a flavonolignan extracted from the seeds of *Silybum marianum* and a known antihepatotoxic agent [12]. CCl<sub>4</sub> mediated liver injury is attributed to the

production of free radicals [13,3]. The trichloromethyl radical reacts with membrane components and is responsible for attacking polyunsaturated fatty acids, leading to membrane lipid peroxidation.

This lipid peroxidative degradation of biomembranes is one of the major principle causes of hepatotoxicity of CCl<sub>4</sub> [14, 15]. This has been confirmed in the present study by elevated levels of GPT, GOT and peroxides. But the plant extract and silymarin reversed these levels.

Extract and silymarin treated group have increased level of ALP; it may be due to the increased synthesis of ALP by the recovering

biliary canicular and hepatic cells as it is evidenced from the increased level of albumin in the blood, a marker of hepatic synthetic function (Table1) [16]. From the ALP level of extract / CCl<sub>4</sub> treated group, it was understood that the extract has no choleretic effect.

The plant extract has significantly increased the serum levels of total protein and albumin, indicating its hepatoprotective activity. Stimulation of protein synthesis has been advanced as a contributory hepatoprotective mechanism, which accelerates the regeneration process and the production of the liver cells [17].

In the present study, a significant decrease in cholesterol and triglyceride levels of serum was observed in CCl<sub>4</sub> treated rats compared to the control group. It may be due to an impairment of lipoprotein synthesis or a decreased transport of lipid components from the liver to serum [18]. The extract treated reversed the changes in the lipid profiles of serum.

Carbon tetrachloride administration is reported to increase the susceptibility of certain types of phospholipids to peroxidative attack, leading to enhancement of their breakdown [19]. This effect combined with impairment in their

synthesis due to liver parenchymal cells might have been the cause of the observed depletion of the phospholipid content of the liver. The depletion was prevented by extract administration. Glutathione levels were not affected in CCl<sub>4</sub> treated groups.

The results of biochemical observations are supplemented by histopathological examination of rat's liver sections. The histological changes induced by CCl<sub>4</sub> treatment was altered by the administration of *F. trinervia*.

In this study, a failure of antioxidant defense mechanisms to prevent formation of excessive free radicals in CCl<sub>4</sub> treated rats was evidenced from high level of lipid peroxides. Pretreatment with the extract retained the defense mechanism possibly due to its antioxidant effect. Our results suggest that the methanolic extract of *F. trinervia* prevents fatty liver, and exhibits antioxidant activity and protects liver from severe damage caused by CCl<sub>4</sub>.

## 5. Acknowledgement

The authors are grateful and thank Dr. V. Arumugam for his support in histopathological studies.

## References

1. Yoganarasimhan SN, Chelladurai V. (2000) *Medicinal Plants of India*, Vol II, Cyber Media: Bangalore; 233.
2. Mary Lou Quinin. (2003) *NAPRALERT DATABASE*, (Net) update: AUG 1.
3. Johnston DE, Kroening C. (1998) *Pharmacol. Toxicol.* 83: 231-239.
4. Subrata De, Ravishankar B, Bhavsar GC. (1994) *Planta Med.* 60: 301-304.
5. Gowenlock AH, McMurray JR, McLauchlan DM. (1988) *Varley's Practical Clinical Biochemistry*, 6th Edn., CBS Publishers: New Delhi; 401-435.
6. Raghuramulu N, Nair KM, Kalyanasundaram S. (1983) *A Manual of Laboratory Techniques, National Institute of Nutrition: ICMR, Hyderabad, India*; 85,92,93, 246-253.
7. Varley H. (1969) *Practical Clinical Biochemistry*, William Heinemann Medical Book Ltd: London.
8. Lowry DN, Rosenbrough NJ, Farr AL, Randall RR. (1951) *J. Biol. Chem.* 193: 265-275.

9. Ohnishi T, Suzuki T, Suzuki Y, Ozawa K. (1982) *Biochem. Biophys. Acta.* 684: 67-74.
10. Beutler E, Duron O, Kelly BM. (1963) *J. Lab. Clin. Med.* 61 : 882-888.
11. Fiske GH, Subbarow Y. (1925) *J. Biol. Chem.* 66: 375-400.
12. Koul IB, Kapil A. (1993) *Planta Med.* 59: 413-417.
13. Srivastava SP, Chen NQ, Holtzman JL. (1990) *J. Biol. Chem.* 265 : 8392-8399.
14. Cotran RS, Kumar V, Robbins SL. (1994) *Robbin's Pathologic Basis of disease*, 5th Edn., Prism Book Pvt. Ltd; 379-430.
15. Kaplowitz N, Aw TY, Simon FR, Stolz A. (1986) *Ann. Int. Med.* 104: 826-839.
16. Dawn BM, Allan DM, Collen MS. (1996) *Basic Medical Biochemistry*, Williams and Wilkins: USA; 584.
17. Awang D. (1993) *Can. Pharm. J.* 23: 749-754.
18. Martin DW, Mayes PA, Rodwell VM. (1983) *Harper's Review of Biochemistry*, 2nd Edn., Lange Medical Publication: Maruzen Asian Edn; Singapore.
19. Farber JL, Gerson RJ. (1984) *Pharmacol. Rev.* 36: 71(s).