



Assessment of hepatoprotective and free radical scavenging effects of *Rhinacanthus nasuta* (Linn.) Kurz in Wistar rats

S. R. Suja¹, P. G. Latha^{1*}, P. Pushpangadan², S. Rajasekharan¹.

1. Ethnomedicine and Ethnopharmacology Division, Tropical Botanic Garden and Research Institute, Palode, Thiruvananthapuram 695 562, India.

2. National Botanical Garden and Research Institute, Lucknow 226 001, India

Abstract

Objective: To evaluate the hepatoprotective and free radical scavenging properties of *Rhinacanthus nasuta*. **Materials and methods:** The methanolic extract of the aerial parts of *R. nasuta* (RN) was tested for its hepatoprotective properties by using paracetamol, to induce liver injury in Wistar rats. Free radical scavenging effects (superoxide, hydroxyl and lipid peroxide) were studied *in vitro* using standard procedures. **Results:** RN significantly protected the liver from paracetamol-induced liver damage as evidenced from decreased level of serum enzymes and an almost normal architecture of the liver of RN treated rats. It also significantly scavenged free radicals (superoxides, hydroxyl and lipid peroxides) from the *in vitro* system. **Conclusion:** RN possessed significant hepatoprotective and free radical scavenging effects.

Keywords: *Rhinacanthus nasuta*, Paracetamol-induced liver damage, Hepatoprotective effect, Free radical scavenging effects, Inhibition of lipid peroxides.

1. Introduction

Rhinacanthus nasuta (Linn.) Kurz of the family, Acanthaceae is an undershrub with white solitary flowers, widely distributed throughout India, Ceylon and Madagascar. It is extensively used in traditional medicine to treat skin diseases, peptic ulcer, helminthiasis, scurvy, inflammation and obesity [1]. In indigenous system of medicine, the roots and leaves of *R. nasuta* are used to treat herpes and other viral infections [2, 3]. It is used in the tribal system of medicine

of Kerala to treat liver diseases (Dr. S. Binu, personal communication). These facts prompted us to study the hepatoprotective effects of the aerial parts of *R. nasuta*.

2. Materials and methods

2.1 Plant Material

The aerial parts of *R. nasuta* were collected from Trivandrum, Kerala. It was authenticated by Dr. Mathew Dan, plant taxonomist of the

*Corresponding author

E - mail: lathagopalakrishnan@yahoo.com

Institute. A voucher specimen (TBGT 41616 dtd. 25/2/03) has been deposited at the Herbarium of the Institute.

It was shade – dried and powdered. The powder (100 gm) was then extracted with 1000 ml methanol, using a Soxhlet's apparatus and the solvent removed by evaporation, at low temperature, under reduced pressure in a rotary evaporator. The extract was referred to as RN (yield : 4.4%). For administration, the plant extract, RN was suspended in 0.5% Tween - 80 to required concentrations.

2.2 Animals

Male Wistar albino rats, (150 - 200 gms) and male Swiss albino mice, males (20 - 25 gms), obtained from the Institute Animal House were used. They were housed under standard conditions and fed commercial rat feed (Lipton India Ltd, Mumbai, India) and water *ad libitum*. All experiments involving animals were done, according to NIH guidelines, after getting the approval of the Institute's Animal Ethics Committee.

2.3 Paracetamol - induced Hepatotoxicity Studies

Paracetamol (Acetaminophen - Sigma Chemical Company, USA) was suspended in 0.5% gum acacia and administered p.o., at a dose of 2.5gm/kg. This dose is known to cause liver damage in rats [4]. The rats were divided into 5 groups (6 / group). Group I, the normal control group was given a single daily dose of 0.5 % Tween-80 p.o., for 4 days.

Group II (paracetamol control group) received a daily dose of 0.5 % Tween-80 for 4 days and a single dose of paracetamol suspension (2.5 gm/kg) p.o., on day 3. Group III, IV, V received daily dose of RN extract p.o., for 4 days (50 mg/kg, 100 mg/kg and 200 mg/kg) and a single dose of paracetamol suspension (2.5 gm/kg), p.o., on day 3.

Animals were sacrificed 48 h after paracetamol administration by mild ether anaesthesia. Blood and liver samples from all the five groups were collected for biochemical and histological studies. The dose and route of administration of the RN extract was based on our previous experiments.

2.4 Assessment of liver function

Biochemical parameters like serum enzymes - serum glutamate oxalo- acetate transaminase (SGOT), serum glutamate pyruvate transaminase (SGPT), serum bilirubin (SB) and serum alkaline phosphatase (SAKP) were assayed, according to standard methods described elsewhere [5-7]. The experiment was repeated twice.

2.5 Histological studies

The liver specimens obtained from the control and the treated groups of the above experiment were trimmed to small pieces and preserved in formalin (10 % solution) for 24 h. They were subjected to dehydration with acetone of strength 70, 80 and 100 % respectively, each for 1 h.

The infiltration and impregnation was done by treatment with paraffin wax, twice each time for 1 h. Paraffin wax was used to prepare paraffin "L" moulds, according to the procedure reported earlier. [8]. Specimens were cut into sections of 3-7 μ m thickness and were stained with haematoxylin and eosin. Mounting of the specimen was done by the use of Distrene Phthalate Xylene (D.P.H.)

2.6 In vitro free radical scavenging effects

Hydroxyl radical scavenging - Hydroxyl radicals generated from Fe^{3+} - ascorbate - EDTA - H_2O_2 were estimated by their degradation of deoxyribose, that resulted in thiobarbituric acid reacting substances (TBARS) formation. The reaction mixture contained deoxyribose (2.8 mM), FeCl_3 (0.1 mM), KH_2PO_4 - KOH buffer (20 mM, pH 7.4), EDTA (0.1 mM), H_2O_2 (1.0

mM), ascorbic acid (0.1 mM) and various concentrations of RN extract, in a final volume of 1 ml. The reaction mixture was incubated at 37°C for 1 h. Degradation of deoxyribose was measured by the thiobarbituric acid method [9] and percentage inhibition was calculated. Curcumin (Bombay Oil Industries Ltd., Angamali, Kerala) was used as the reference compound. [10]. The experiment was done thrice.

Assessment of superoxide radical scavenging activity: - Superoxide radical scavenging activity of RN extract was determined by the Nitroblue tetrazolium (NBT) reduction method [11]. The reaction mixture contained EDTA (0.1 M), 0.0015% NaCN, riboflavin (0.12 mM), NBT (1.5 mM) and various concentrations of RN extract and phosphate buffer (67 mM, pH 7.8), in a total volume of 3 ml.

The tubes were illuminated under an incandescent lamp for 15 min and thereafter, the optical density was measured at 530 nm. The percentage inhibition of superoxide production was evaluated by comparing the absorbance of the control and experimental tubes. Curcumin was used as the reference compound. The experiment was repeated thrice.

Inhibition of lipid peroxide formation by Fe³⁺/ascorbate system – The anti - lipid peroxidation effects of RN was studied *in vitro*, according to the methods reported earlier [12, 13]. Briefly, 2 gm of rat liver tissue was sliced and homogenised with 150 mM KCl - Tris HCl buffer (pH 7.2). The reaction mixture was composed of 0.25 ml liver homogenate, Tris HCl buffer (pH 7.2), 0.1 mM ascorbic acid (AA), 4 mM FeCl₃ and 0.05 ml of various concentrations of RN extract. The mixture was incubated at 37°C for 1 h in a capped tube.

Then, 0.1N HCl, SDS (9.8%), 0.9 ml distilled water and 2 ml thiobarbituric acid (0.6%) were

added to each tube and vigorously shaken. The tubes were placed in a boiling water bath at 100°C for 30 min. After cooling, 5 ml of butanol was added and centrifuged at 3000 rpm for 25 min. The absorbance of the supernatant was measured at 532 nm. Curcumin was used as the reference compound.

Protein content was determined as described elsewhere [14], using bovine serum albumin as the standard. The experiment was repeated twice. IC₅₀ values for superoxide, hydroxyl and lipid peroxide inhibition were determined by graphical extrapolation as reported earlier [15].

2.7 Behavioural effect and toxicity

Three groups of ten mice were treated with graded doses (100, 200 and 400 mg/kg) of the RN extract, p.o. They were observed continuously, for 1 h for any gross behavioural changes and death, if any, and then intermittently for the next 6 h and then again at 24 h after dosing with RN extract.

2.8 Statistical analysis

The results were expressed as mean ± SD. Analysis of variance (ANOVA) was done to compare and analyse the data followed by Duncan's multiple range test. Effects were considered significant at P < 0.05 in all cases. [16]

3. Results

Administration of paracetamol caused a significant increase in serum enzymes namely SGOT, SGPT, SAKP and SB in rats as compared to controls. Pretreatment with the plant extract RN (100 mg/kg and 200 mg/kg) prior to paracetamol administration caused significant reduction in the values of these parameters. However, the lowest dose used (50 mg/kg) did not cause significant reduction of serum enzyme levels. (Table 1)

Histological architecture of paracetamol- treated liver sections showed fatty degeneration of

Table 1

Effect of *Rhinacanthus nasuta* methanolic extract (RN) on rat serum enzymes after paracetamol administration.

Groups	SGOT (IU / L)	SGPT (IU / L)	SAKP (KA units/100 ml)	SB (mg %)
Normal control	50.46 ± 1.85 ^c	37.8 ± 2.16 ^e	79.94 ± 2.29 ^e	1.42 ± 0.47 ^b
Paracetamol control (2.5 gm / kg)	155.31 ± 1.32 ^a	181.7 ± 1.53 ^a	140.55 ± 3.33 ^a	1.60±0.26 ^a
Paracetamol (2.5 gm/kg) + RN (50 mg / kg)	129.46±4.93 ^b	158.3±3.2 ^b	121.0±3.96 ^b	1.40±0.23 ^b
Paracetamol (2.5 gm/kg)+ RN (100 mg / kg)	37.08 ± 1.78 ^e	90 .0± 5.98 ^d	88.0 ± 4.98 ^d	0.50 ± 0.16 ^d
Paracetamol (2.5 gm/kg)+ RN (200 mg / kg)	39.15 ± 3.97 ^d	124.9 ± 4.47 ^c	103.0 ± 1.81 ^c	1.10±0.10 ^c

Values are expressed as mean±SD; n=6; Analysis of variance (ANOVA) followed by Duncan's multiple range test; means bearing different superscripts differ significantly. (P< 0.05)

hepatocytes with nuclear pycnosis and karyolysis. RN treatment (100 mg / kg) almost normalised these defects in the histological architecture of the liver, showing its potent hepatoprotective effects. (Figs. 1-3).

RN extract was found to scavenge the superoxides generated by riboflavin photo-reduction method (Table 2). The IC₅₀ of RN extract for superoxide radical generation was 110 mg /ml.

Degradation of deoxyribose by hydroxyl radicals generated by Fe³⁺ ascorbate/EDTA/H₂O₂ was also found to be inhibited by the RN extract. The IC₅₀ of RN extract for hydroxyl radical generation was 68 µg/ml. (Table 2). RN extract inhibited lipid peroxides generated by Fe²⁺/ascorbate system in rat liver homogenate. The IC₅₀ of the RN extract for *in vitro* lipid peroxidation was 115 µg/ml. (Table 2).

The IC₅₀ of curcumin required for superoxide, hydroxyl and lipid peroxide generation was 6.14, 2.69 and 8.4 µg/ml respectively. (Table 2)

Toxicity studies revealed no mortality occurred within 24 h, with the 3 doses of RN tested. The LD₅₀ was therefore greater than 400 mg/kg. (data not shown). The treated animals did not show any changes in general behaviour during the study.

4. Discussion

Paracetamol is a well-known antipyretic and analgesic, which produces hepatic necrosis at higher doses. Indiscriminate ingestion can lead to accidental poisoning and potentially lethal hepatotoxicity. Its mode of action in liver is by covalent binding of its toxic metabolite, n-acetyl p-benzoquinoneamine to tissue macro-molecules, resulting in cell necrosis [17].

Damage to the structural integrity of liver is reflected by an increase in the levels of serum transaminases, because they are cytoplasmic in location and are released into the circulation after cellular damage [18, 19]. Protection against paracetamol-induced toxicity has been

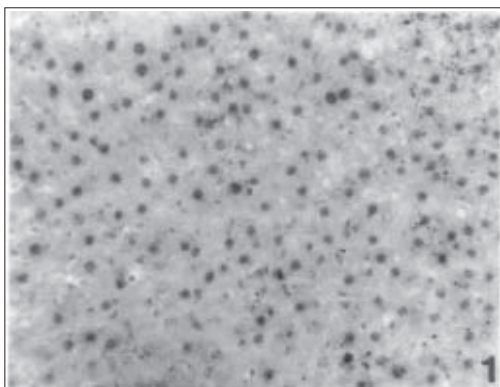


Fig. 1. Section of normal rat liver showing hepatic cells with prominent nuclei and cytoplasm (x 200).

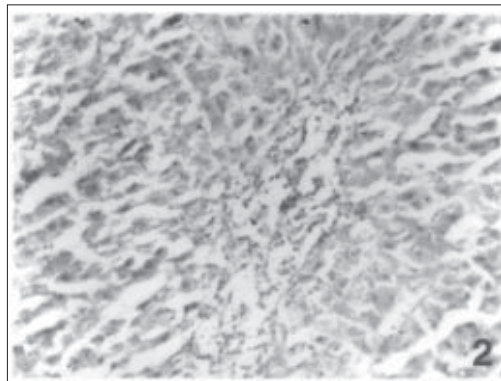


Fig. 2. Section of paracetamol (2.5 gm / kg) treated rat liver, showing widespread necrosis, fatty degeneration and cloudy swellings (x 200).

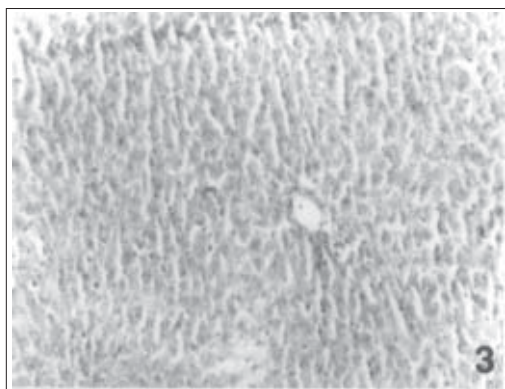


Fig. 3. Section of paracetamol (2.5 gm / kg) + *Rhinacanthus nasuta* (100 mg/kg) treated rat liver, showing an almost normal architecture (x 200).

used as a test for a potential hepatoprotective agent by several investigators [20, 21].

Pretreatment of the rats with 100 mg/kg and 200 mg/kg p.o., of RN extract before paracetamol administration resulted in a significant protection from paracetamol-induced elevation of serum marker enzymes, with the lower dose (100 mg/kg), being more effective than the higher dose (200mg/kg), used in the present study. The lowest dose used in the study (50 mg / kg) did not cause significant reduction of serum enzymes.

Elevation of serum enzyme levels is considered as an index of diagnosis of liver diseases [22]. The plant extract RN appeared to be effective in reducing the injurious effect of paracetamol as observed from significant reduction of paracetamol - induced elevated serum enzyme levels. It was also seen that histopathological damages induced by paracetamol were improved in rat liver, treated with RN extract.

This implies that concomitant administration of RN prevented hepatonecrotic changes, induced by the toxic dose of paracetamol, indicating the ability of RN, to preserve the normal functional status of the liver. These findings are in agreement with the commonly accepted view, that serum levels of transaminase return to normal with healing of hepatic parenchyma and regeneration of normal hepatocytes [23].

Free radicals cause damage in biological systems. This in turn cause cellular damage that may lead to cancer, liver injury, heart diseases etc. [24]. The results of the present study indicate that RN whole plant extract inhibits oxygen radicals such as superoxide, hydroxyl and lipid peroxides. The concentration of RN (aerial

Table 2

Effect of *Rhinacanthus nasuta* methanolic extract (RN) on *in vitro* free radical (superoxide, hydroxyl and lipid peroxide) generation

Tested material	IC 50 (mg / ml)		
	Superoxide	Hydroxyl	Lipid peroxides
Methanol extract	110 (90 - 130)	68 (55 - 81)	115 (105 - 120)
Curcumin	6.14 (4.14 - 8.30)	2.69 (2.64 - 2.74)	8.40 (6.12 - 9.70)

Confidence limits within parentheses.

parts) extract required for *in vitro* inhibition of these oxygen radicals was higher than that of a known antioxidant like curcumin.

The free radical scavenging (antioxidant) property of RN extract may be responsible for the observed hepatoprotective effects of the present study. Natural products like coumarins, flavonoids and lignans have the potential of reducing the deleterious effects of free radicals [25-27]. RN is reported to contain flavonoids, lignans, triterpenes etc [2, 3] and these may be responsible for the observed antioxidant properties in the present study.

The RN extract is non - toxic up to 400mg/kg, p.o. This is not surprising, as it is an ingredient

of several tribal medicinal formulations used for liver diseases, and viral infections.

The present study thus supports the view that RN requires further detailed studies for its bioactive principles, to evaluate its potential in the treatment of liver diseases.

5. Acknowledgements

The authors thank Dr. G. Sreekandan Nair, the Director of the Institute for facilities, Mr. S. Radhakrishna Pillai for technical assistance, Dr. William Decruse for help with statistical analysis and Mr. S. Suresh Kumar for photography. The financial assistance from the Kerala State Planning Board, Thiruvananthapuram is gratefully acknowledged.

References

- Warrier PK, Nambiar VPK, Ramankutty C. (1995) *Indian Medicinal Plants - A Compendium of 500 Species*, Vol IV, Orient Longmans, India ; 417 - 420
- Sendi A, Chen JL, Jolad SD, Stoddart CA, Roshan E, Kernan M. (1996) *J. Nat. Prod.* 59: 808 - 811.
- Kernan MR, Sendi A, Chen JL, Jolad SP, Blanc P, Murphy JT, Stoddart CA, Nanakorn W, Balick MJ Rozhon EJ. (1997) *J. Nat. Prod.* 60: 635 - 637
- Mitra SK, Venkataranganna MV, Sundaram K, Gopumadhavan S. (1998) *J. Ethnopharmacol.* 63: 181 - 186.
- Reitman S, Frankel S. (1957) *Amer. J. Clin. Path.* 28: 56 - 66.
- Malloy HT, Evelyn KA. (1937) *J. Biol. Chem.* 119 : 481 - 490.

7. King EJ, Armstrong AR. (1980) In: Varley B, Gowenlock A H, Bell M. (Eds.) *Practical Clinical Biochemistry* Vol 1. Heinemann: London; 850 - 860
8. Mukharjee KL. (1995) *Medical Laboratory Technology*. Vol.3, Tata McGraw - Hill Publication Company Ltd.: New Delhi; 1111 - 1123
9. Ohkawa H, Ohishi N, Yagi K. (1979) *Anal. Biochem.* 95: 351 - 358.
10. Jose JK, Kuttan R. (1995) *J. Clin. Biochem. Nutr.* 19: 63 - 70
11. McCord JM, Fridovich I. (1969) *J. Biol. Chem.* 244 : 6049 - 6055.
12. Yoshiyuki K, Michinori K, Todato T, Shigeru A, Hiromichi O. (1981) *Chem. Pharm. Bull.* 29: 2610 - 2617.
13. Masao H, Yang SW, Miyashiro H, Namba T. (1997) *Phytother. Res.* 7: 395 - 401.
14. Lowry OH, Rosebrough NJ, Farr AL, Randall RJ. (1951) *J. Biol. Chem.* 193: 265- 275.
15. Ghosh MN. (1971) *Fundamentals of experimental pharmacology*, Scientific Book Agency: Calcutta; 112.
16. Raghava RD. (1987) *Statistical techniques in agricultural and biological research*. Oxford & IBH Publishing Co.: New Delhi ; 200.
17. Mitchell JR, Jollow DJ, Potter WZ, Gillete JR, Brodie BN. (1973) *J. Pharmacol. Exp. Ther.* 187 :185 - 194.
18. Schmidt E, Schmidt FW, Mohr J, Otto P, Vido I, Wrogeman K, Herfarth C. (1975) In: Keppler D. (Ed.) *Pathogenesis and Mechanism of Liver Cell Necrosis*. Medical and Technical Publications: Lancaster, UK; 147 -155
19. Sallie R, Tredger JM, William R. (1991) *Biopharmaceut. Drug Deposition.* 12: 251 - 259.
20. Dwivedi Y, Rastogi R, Garg NK, Dhawan BN. (1991) *Phytother. Res.* 59 :115 –119.
21. Shukla B, Visen PKS, Patnaik GK, Dhawan BN. (1991) *Planta Med.* 57 : 29 – 33.
22. Mahendale HM. (1985) In: Gupta PK, Shalunke DK. (Eds.) *Modern Toxicology*. Vol 1, Metropolitan Books: New Delhi; 225 - 276
23. Thabrew MI, Joice PD, Rajatissa W. (1987) *Planta Med.* 53 : 239 - 241.
24. Halliwell B, Gutteridge JMC. (1985) *Free radicals in biology and medicine*, 1st edn. Clarendon Press: Oxford; 279 -285
25. Chen YY, Shu ZB, Li LN. (1976) *Scientica Sinica* 19: 276 - 290.
26. Hoefler C, Mortier F, Fluentin J, Pelt JM, Guillemain J. (1980) *Biruniya Rabatt Maroc.* 2 ; 79 - 89.
27. Faure M, Lissi E, Torres R, Videla LA. (1991) *Phytochemistry* 29 : 3773 - 3775